

# Compensatory orthodontic treatment for maxillary deficiency: A 4-year follow-up

Giordani Santos Silveira,<sup>a</sup> Johnny Holanda de Gauw,<sup>a</sup> Alexandre Trindade Motta,<sup>b</sup> and José Nelson Mucha<sup>c</sup>  
Niterói, Rio de Janeiro, Brazil

In this article, we report the orthodontic treatment of a boy (age 12 years 9 months) who had a midface deficiency, a concave facial profile with maxillary retrusion, a complete crossbite (anterior and posterior), and the maxillary right canine retained in the alveolus. Rapid maxillary expansion was performed followed by complete orthodontic treatment with fixed appliances combined with Class III elastics and anterior vertical elastics. Time was allowed to elapse until growth was virtually over before removing the fixed appliances (at age 18 years 4 months), and no retainer of any type was used. As a result of treatment, significant improvement was noted in his facial appearance, with a proper maxillomandibular relationship, total correction of the maxillary atresia, and satisfactory overjet and overbite. The results remained stable at the 4-year follow-up. Therefore, it can be argued that the use of Class III elastics combined with rapid maxillary expansion has a beneficial effect in the treatment of transverse and sagittal maxillary deficiency in growing patients. Excellence in how the treatment was finished and discontinuation of treatment and control in the final stages of growth contributed to the stability of the final results. (*Am J Orthod Dentofacial Orthop* 2014;146:227-37)

Despite a lower prevalence of Angle Class III malocclusion compared with Class I and Class II in the population, treating the former poses a daunting challenge to the orthodontist, especially in patients with skeletal involvement.<sup>1,2</sup> The therapeutic options available for correction of Class III malocclusion in growing patients include the use of a chin cup,<sup>3</sup> expansion and reverse pull of the maxilla,<sup>4,5</sup> functional orthopedic appliances,<sup>6,7</sup> headgear for the mandibular arch,<sup>8</sup> and Class III elastics.<sup>9</sup>

Inducing a clockwise rotation of the mandible to correct a Class III relationship and improve the facial profile by moving the chin downward and backward is a rather common strategy today.<sup>9,10</sup> There are, however, 2 caveats to this approach. First, it should not be used in patients with a high mandibular plane angle, increased lower anterior face height, and open bite. These features are common in skeletal Class III malocclusions.<sup>11</sup> Second,

the stability of treated patients is more intimately related to therapeutic approaches that achieve an adequate overbite without producing mandibular clockwise rotation.<sup>9,11-13</sup>

This case report describes the orthodontic treatment performed on a boy with maxillary sagittal and transverse deficiencies between the ages of 12 and 18 years. Rapid maxillary expansion (RME) was used, followed by fixed orthodontic appliances with Class III and vertical elastics. The results remained stable after 4 years without any kind of retention.

## DIAGNOSIS AND ETIOLOGY

A boy, aged 12 years 9 months, came to the Department of Orthodontics of Fluminense Federal University in Brazil accompanied by his mother and seeking orthodontic care. His major complaints were retrusion of the upper lip, lack of maxillary teeth, dental misalignment, and compromised phonation. The medical history showed that the patient was taking carbamazepine (200 mg) to prevent seizures; this did not contraindicate orthodontic therapy.

The extraoral examination disclosed a slightly concave profile with deficiency in the midface and retrusion of the upper lip relative to the lower lip. In the front view, there were symmetry, passive lip seal, normal smile line, and deviation of the maxillary teeth to the right (Fig 1). There was some deviation in the mandibular closing pattern and clicks in the temporomandibular

From the Department of Orthodontics, Fluminense Federal University, Niterói, Rio de Janeiro, Brazil.

<sup>a</sup>Postgraduate student.

<sup>b</sup>Associate professor.

<sup>c</sup>Professor and chair.

All authors have completed and submitted the ICMJE Form for Disclosure of Potential Conflicts of Interest, and none were reported.

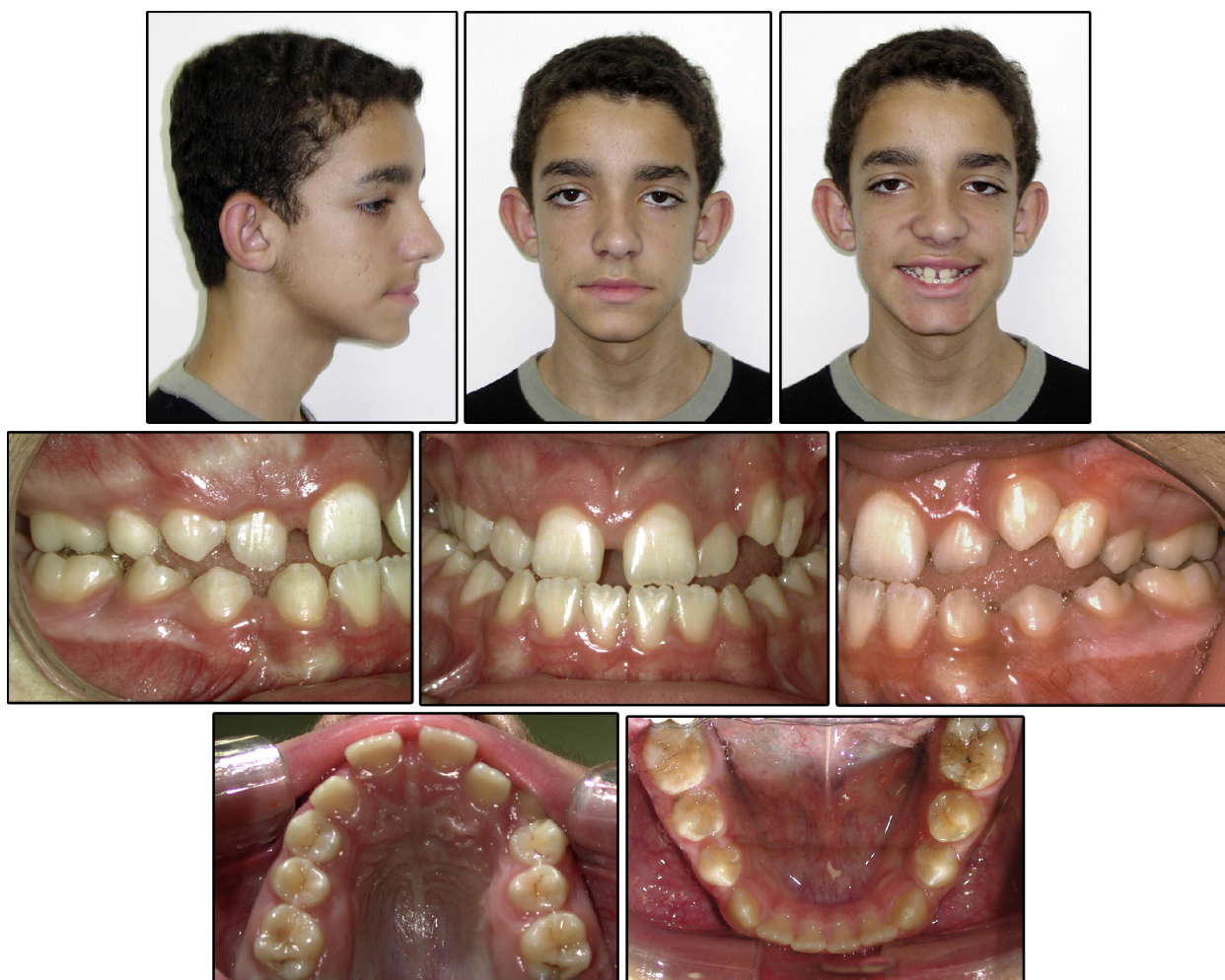Address correspondence to: Alexandre Trindade Motta, Av. Gilberto Amado, 1102/301 Rio de Janeiro, RJ, Brazil 22621-232; e-mail, [alemotta@rjnet.com.br](mailto:alemotta@rjnet.com.br).

Submitted, September 2013; revised and accepted, October 2013.

0889-5406/\$36.00

Copyright © 2014 by the American Association of Orthodontists.

<http://dx.doi.org/10.1016/j.ajodo.2013.10.023>



**Fig 1.** Pretreatment photographs.

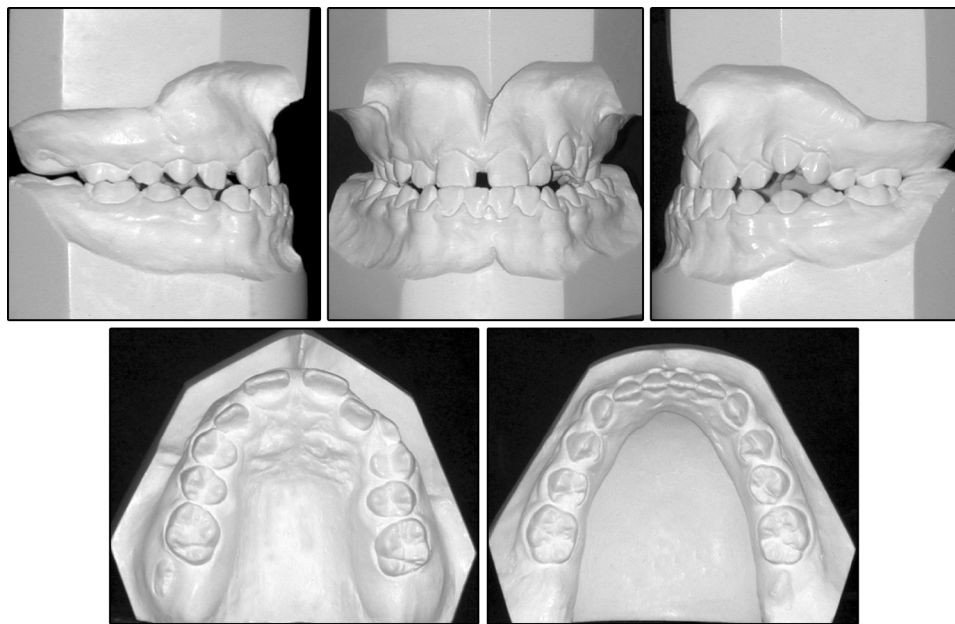
joints. Swallowing, phonation, and tongue position were also altered. In addition, the patient displayed oral breathing, although his nose breathing was intact.

Intraorally, the maxillary arch was totally circumscribed by the mandibular arch, which characterized a complete crossbite (both anterior and posterior). The lack of space in the maxilla amounted to 11.6 mm, with a lack of space also for both canines. The maxillary right canine was totally retained. The mandibular arch, in turn, showed a positive discrepancy of 3 mm. Overjet was  $-1$  mm (negative), and the right incisors were shifted to the right, with a related diastema. The molar relationship was Class I, and there was an open bite in the region of the left canines (Fig 2).

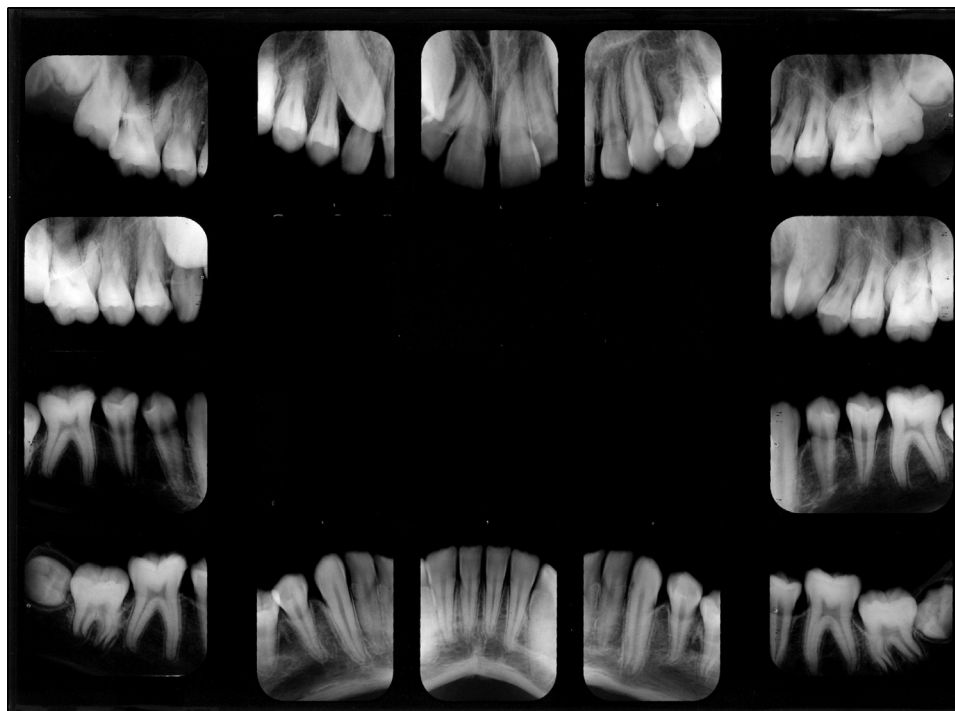
The radiographic examination (Figs 3 and 4) showed the presence of all teeth, including the third molars in

the final stages of crown formation, with the maxillary third molars showing some distal tip and the mandibular third molars some mesial tip. The maxillary right canine could be visualized and had a slight mesial tip. It was impacted between the roots of the lateral incisor and the right first premolar. No changes were noted in the bone or the periodontal and periapical aspects.

The cephalometric analysis (Figs 5 and 6; Table) disclosed maxillary retrusion relative to the cranial base (SNA,  $77^\circ$ ; SNB,  $80^\circ$ ; ANB,  $-3^\circ$ ), and the relationship between the basal bones as measured by AO-BO (Wits appraisal) was  $-8$  mm. There was a favorable vertical relationship (SN, GoGn,  $30^\circ$ ; FMA,  $27^\circ$ ), a concave skeletal profile (facial convexity,  $-10^\circ$ ), and an unbalanced lip relationship (S-LS,  $-4$  mm; S-LI,  $+3$  mm). The maxillary incisors protruded labially (1-NA, 8 mm; 1.NA,  $28^\circ$ ),



**Fig 2.** Pretreatment dental casts.



**Fig 3.** Pretreatment periapical radiographs.

and the mandibular incisors had a moderate labial inclination (1-NB, 6 mm; 1.NB, 26°; IMPA, 94°) without signs of Class III compensation. The patient was going

through a stage of active growth; therefore, the intermaxillary sagittal relationship was likely to worsen without intervention.

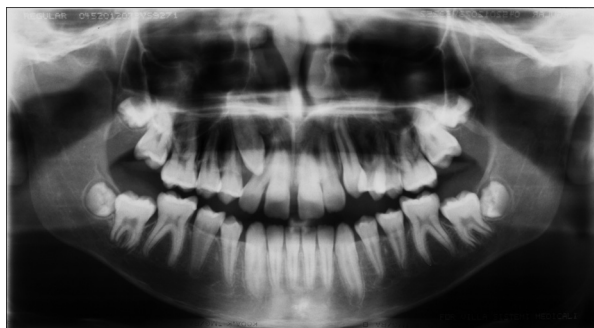

Fig 4. Pretreatment panoramic radiograph.

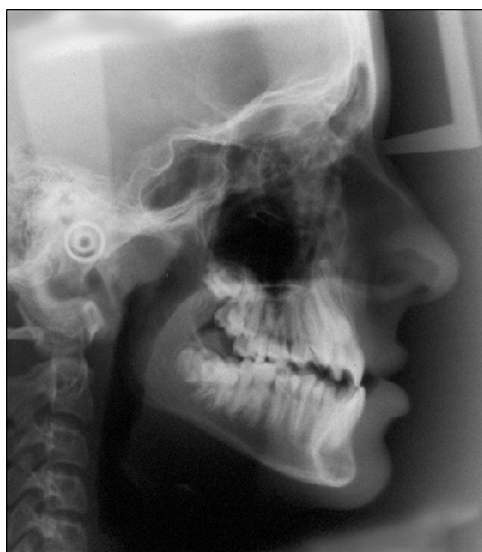

Fig 5. Pretreatment lateral cephalometric radiograph.

### TREATMENT OBJECTIVES

The treatment objectives were to (1) improve the facial appearance by protruding the midface (maxilla) anteriorly and thus correct the unbalanced relationship between the upper and lower lips; (2) correct the posterior and anterior crossbites; (3) improve the dental relationships, especially of the molars and incisors, to achieve proper occlusion with appropriate overjet and overbite; (4) make space for the maxillary canines; (5) achieve a mutually protected functional occlusion with stable and simultaneous occlusal contacts of all teeth in central relationship and eccentric contacts guided by the anterior teeth; (6) eliminate the signs of temporomandibular joint dysfunction; and (7) ensure that the patient breathed mostly through the nose.

### TREATMENT ALTERNATIVES

Three treatment options were considered: 2 orthodontic-orthopedic approaches and 1 orthodontic-

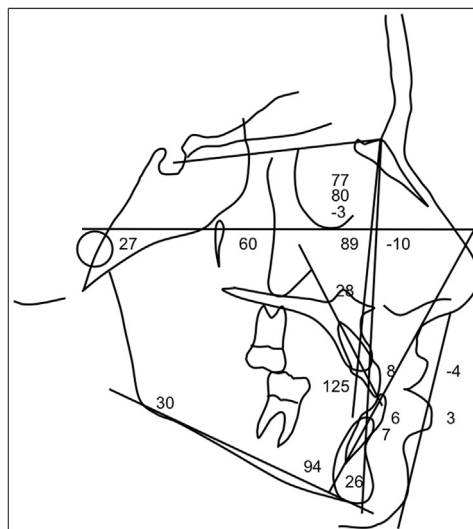


Fig 6. Pretreatment cephalometric tracing and measurements.

surgical approach. The latter would only be carried out if correction by the first 2 alternatives failed. RME using a Haas type of appliance was the first planned intervention, regardless of the treatment to be undertaken in due course.<sup>14,15</sup> It was decided that the first step would be to correct the maxillary atresia, so RME was the procedure of choice. Thereafter, spaces would be created for all the teeth in the maxilla, especially for the right canine. Therefore, the factors that distinguished these therapeutic options had to do with the approaches for sagittal intermaxillary correction.

The first option involved maxillary reverse pull and then placing fixed appliances on both arches, since this is the option most often reported in the literature to correct this kind of problem.<sup>4,5,11,16,17</sup>

The second option comprised the use of Class III elastics supported on the last tooth of the maxillary braces and on hooks placed between the lateral incisors and canines in the mandibular arch, in addition to anterior square elastics. This would be the method used for anteroposterior correction, after the period of retention of the expansion.<sup>18</sup>

The third option would require orthognathic surgery after skeletal maturity if the craniofacial growth proved unfavorable or the patient was not compliant during the previous phases of orthodontic treatment.

A team of orthodontists (students and an instructor) decided that the use of Class III elastics would provide the same mechanical components and action lines as reverse-pull forces combined with a chin cup, and would therefore be more desirable because it is a totally intraoral approach. Thus, the second option was adopted because of the likelihood of achieving greater patient

**Table.** Cephalometric measurements

Measurement	Normal	Pretreatment	Posttreatment	Follow-up
Age		12 y 9 mo	18 y 4 mo	22 y 7 mo
Skeletal pattern				
SNA (°)	82	77	80	80
SNB (°)	80	80	80	80
ANB (°)	2	-3	0	0
Facial convexity (°)	0	-10	-4	-4
Y-axis (°)	59	60	62	63
Facial angle (°)	87	89	90	91
SN.GoGn (°)	32	30	30	31
AO-BO (mm)	-1	-8	-5	-6
Dental pattern				
IMPA (°)	90	94	93	92
I.NA (°)	22	28	30	29
I-NA (mm)	4	8	7	7
I.NB (°)	25	26	24	23
I-NB (mm)	4	6	5	5
I.1 (°)	130	125	127	129
Profile				
Upper lip, S line (mm)	0	-4	-2	-1
Lower lip, S line (mm)	0	3	1	1

compliance with intraoral elastics over the extraoral appliances suggested in the first option.

### TREATMENT PROGRESS

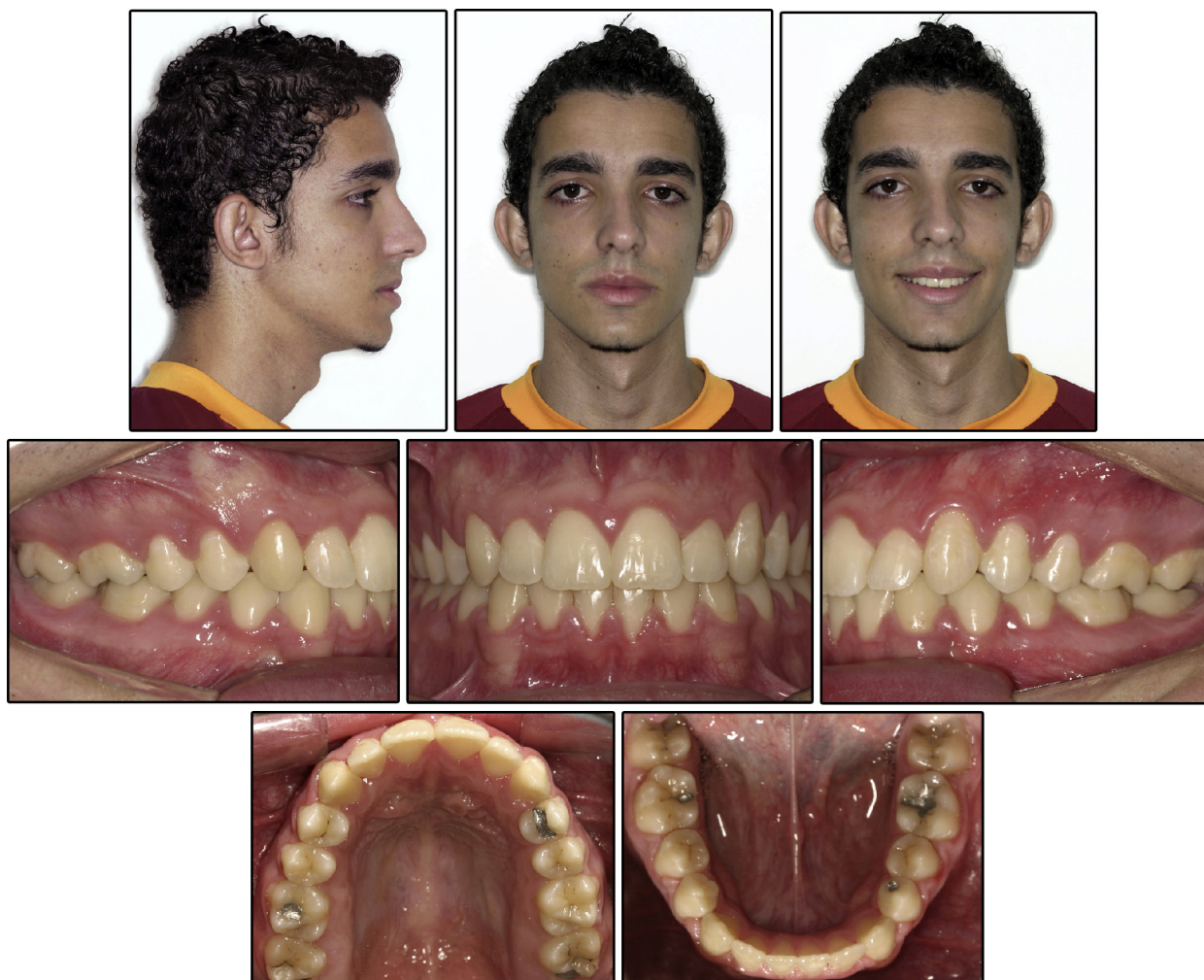A Haas palatal separator was installed with orthodontic bands on the maxillary first premolars and first molars.<sup>14,15,19</sup> The screw was activated twice a day (a quarter turn each time) in the morning and afternoon, until overcorrection of the posterior crossbite was obtained: ie, the internal slopes of the palatal cusps of the maxillary posterior teeth touched the internal slopes of the buccal cusps of the mandibular posterior teeth. This stage was reached after 28 days of activation, with 14 mm of screw opening; subsequently, the screw was stabilized with ligature wire and acrylic resin. According to the treatment plan, the expander would be kept in place as a retainer for 6 to 8 months. It was noted that the bite opened slightly, and the anteroposterior relationship improved.

The Haas appliance was removed after 8 months of retention, and standard edgewise 0.022 × 0.028-in fixed appliances were placed on all teeth. Orthodontic leveling of the maxillary and mandibular arches was performed with nickel-titanium 0.014-in and 0.018-in stainless steel archwires. After creating space for the maxillary right canine with a compressed nickel-titanium open-coil spring, a stainless steel 0.019 × 0.026-in archwire with omega stops placed close to the maxillary first molar tubes (to preserve the space that had been obtained) was fabricated with

delta-shaped hooks placed between the lateral incisors and the canines. This archwire was made expandable to maintain the expansion achieved with the RME. Surgical exposure was indicated, an orthodontic button was bonded, and the canine was pulled with elastomeric chains to its proper position in the arch.

Similarly, a mandibular stainless steel 0.019 × 0.026-in archwire was installed with delta-shaped hooks placed between the lateral incisors and the canines, and with omega loops placed 1 mm from the molar tubes. Individualized first- and third-order bends were carefully incorporated while ensuring that the original form of the mandibular arch was preserved, especially in relation to the intercanine width. Initially, Class III elastics were extended from the mandibular deltas to the tubes on the second molars to obtain proper overjet. Subsequently, anterior vertical elastics attached to the delta-shaped hooks (between the lateral incisors and the maxillary and mandibular canines) reinforced the Class III elastics to achieve proper overbite. The applied force ranged from 250 to 300 g. The patient was asked to use the elastics as long as possible in the 24 hours of the day. The same elastic was used in square fashion in the anterior region. It was placed on the 4 deltas in both arches.

To check that stability had been achieved despite the possibility of residual growth, the orthodontic appliance was retained but elastic mechanics was periodically discontinued. This sequence was repeated twice before the occlusion was definitively stabilized and growth had slowed.



**Fig 7.** Posttreatment facial and intraoral photographs.

The fixed appliance was removed without placement of a retainer in either arch.<sup>18</sup> Total treatment time was 67 months.

#### TREATMENT RESULTS

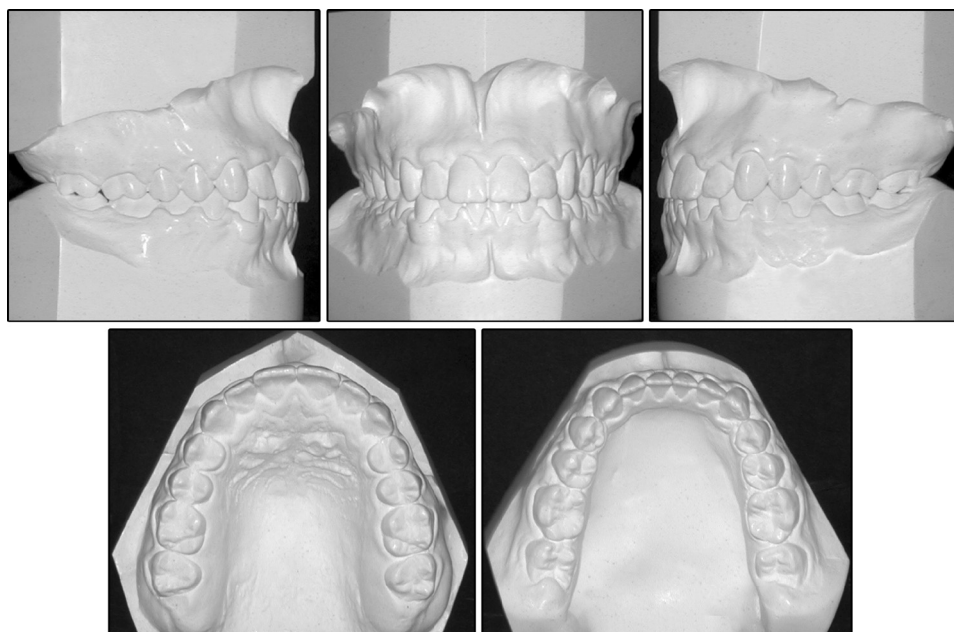
It is noteworthy that during the most active phase of orthodontic treatment, the patient's hygiene started lagging, requiring prophylactic and therapeutic interventions by the orthodontist. As can be seen in [Figure 7](#), the occlusal surfaces of 5 teeth had to be restored. Furthermore, the presence of characteristic spots of enamel demineralization was noted in some teeth as well as some moderate gingival inflammation.

The posttreatment records ([Figs 7-11](#)) show that the goals were achieved. There was significant improvement in the facial appearance, especially in the disharmony between the upper and lower lips, and a balanced

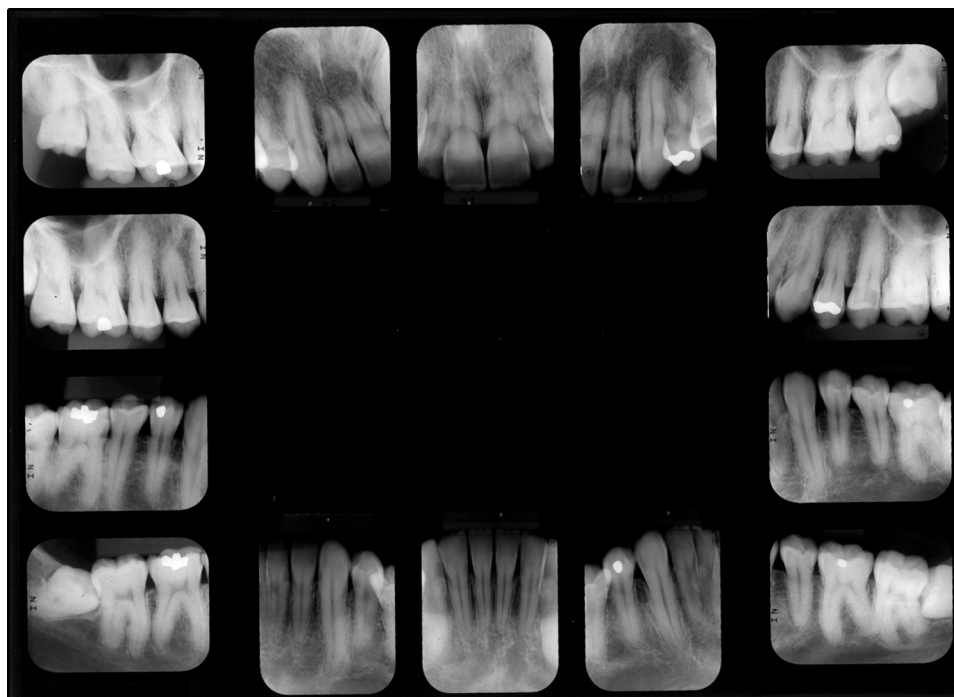
smile with adequate maxillary incisor exposure was obtained.

A proper relationship was established between the 2 arches, with full correction of the maxillary atresia, occlusal contacts with ideal molar and canine occlusions, proper overjet and overbite, and correct and coincident midlines. An anterior functional guide was obtained in the eccentric movements of the mandible; this proved efficient for the canines, and there were no more clicks in the temporomandibular joints and no mandibular shift. The patient's breathing spontaneously became predominantly nasal without the need for treatment.

The horizontal position of the mandibular third molars, whose radiographs suggested a dangerous proximity of their crowns to the distal roots of the second molars ([Figs 9 and 10](#)), prompted the extraction of all



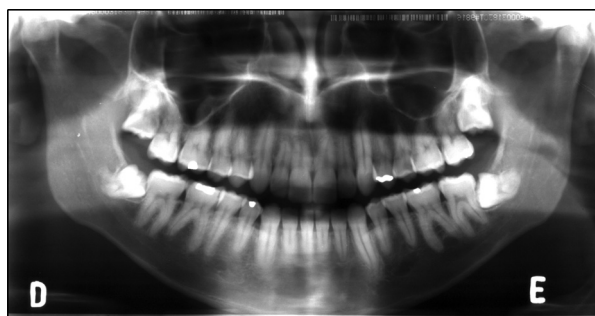
**Fig 8.** Posttreatment dental casts.



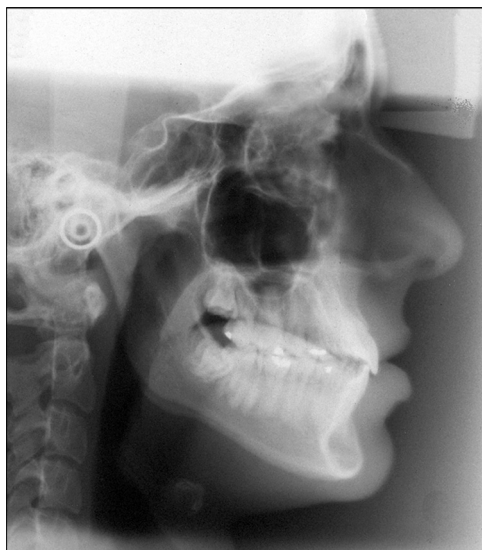**Fig 9.** Posttreatment periapical radiographs.

third molars. By means of radiographic analysis and superimposition of the tracings (Figs 12 and 13; Table), a greater displacement of the maxilla vs the mandible was visualized, which resulted in the

improvement of the relationship between the arches (ANB, 0°; angle of convexity, -4°), flaring of the maxillary anterior teeth (1-NA, 7 mm; 1.NA 30°), retrusion and retroclination of the mandibular incisors (1-NB,



**Fig 10.** Posttreatment panoramic radiograph.



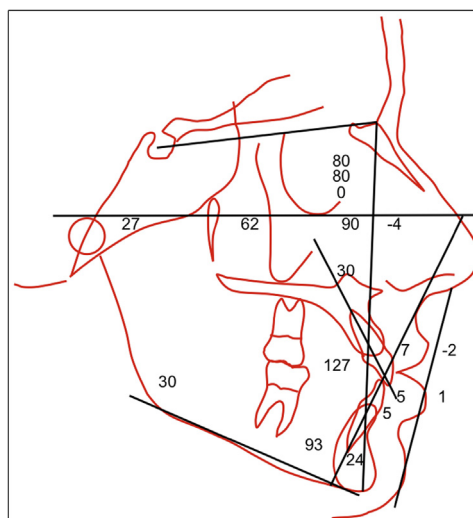
**Fig 11.** Posttreatment lateral cephalometric radiograph.

5 mm; 1.NB, 24°), and maintenance of the mandibular plane angle (SN-GoGn, 30°; FMA, 27°).

Figures 14 and 15 show the patient at 4 years posttreatment. As can be observed, the results remained stable in maintaining both facial balance and intermaxillary dental relationships. From an intra-arch perspective, dental alignment and dental arch form also remained stable. Radiographic analysis showed stability in the maxillomandibular relationship, the position of the mandibular anterior teeth, and the mandibular plane angle (Table).

## DISCUSSION

According to the clinical examination and the facial and cephalometric analyses, the cause of this patient's malocclusion was an underdeveloped maxilla, both transversely and sagittally. The mandible was well positioned in the anteroposterior and vertical directions.



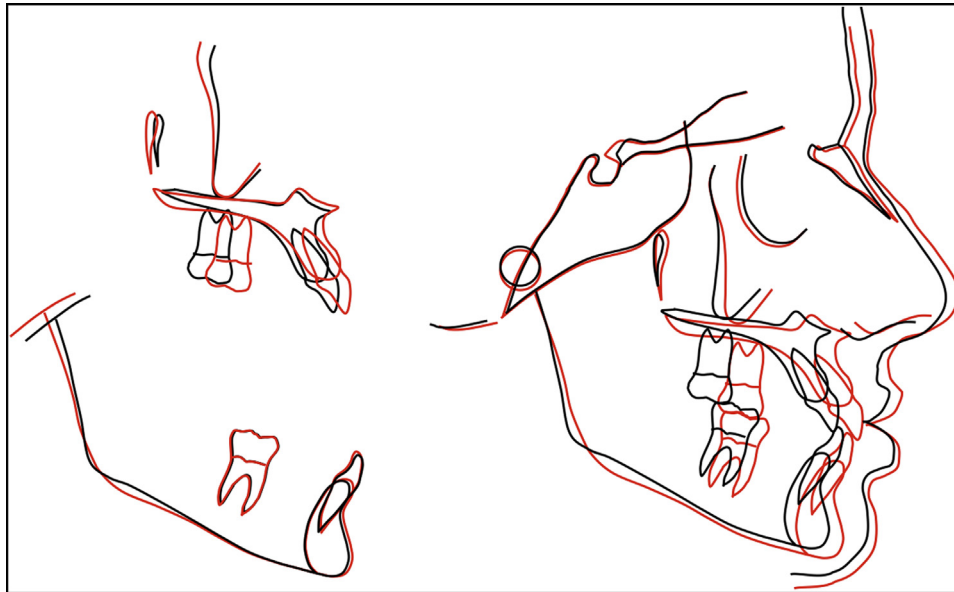
**Fig 12.** Posttreatment cephalometric tracing and measurements.

Since there was no evidence of mandibular prognathism in the examinations and family history reports, the prognosis was favorable. It was obvious that correction would require orthopedic intervention in the maxilla because the patient was in an active growth phase.<sup>14,15,19</sup>

The classic therapy for maxillary retrusion in patients during growth—a palate-splitting appliance followed by a facemask or chin cup—was not used for this patient. This was decided in light of the patient's compliance and the possibility that mesial dental movement might occur instead of skeletal effects, which might result in further reduction of an already limited space for the maxillary canines. The fact that anteroposterior elastic force was applied after insertion of the canines in the arch proved advantageous, since when reverse pull is used, the anteroposterior force is applied immediately after RME.

Another argument that also influenced this decision was the risk of an increase in lower anterior facial height that could result from clockwise rotation of the mandible; this tendency had been previously associated with maxillary reverse pull that, in this case, would invariably impart some instability.<sup>16,17,20,21</sup> Ferro et al<sup>9</sup> reported that the stability of Class III corrections is directly related to the maintenance of the vertical position of the mandible, corroborating what some other authors also advocated.<sup>7,12,13</sup> As described by Björk and Skieller,<sup>22</sup> anterior mandibular rotation is a natural tendency in late adolescent growth, and one must therefore work for and not against facial growth to ensure stable results.<sup>9</sup> Otherwise, when correction is obtained by further rotation of the mandible, the physiologic pattern of forward rotation tends to manifest itself, and relapse occurs.<sup>9</sup>





**Fig 13.** Cephalometric superimpositions: pretreatment vs posttreatment.

Also favorable in this case was the result achieved after anteroposterior palatal expansion. The maxillary and mandibular incisors were practically in an edge-to-edge relationship. The anterior displacement of the maxillary complex caused by RME is well documented in the literature,<sup>19,23,24</sup> despite conflicting results involving its long-term stability.<sup>25,26</sup>

It is noteworthy that by creating space for the maxillary right canine with the aid of the fixed appliance in conjunction with an open spring, some buccal flaring of the maxillary incisor crowns was expected. This adverse effect was partly offset by the use of third-order bends placed in the orthodontic archwires to prevent the crowns from inclining even farther. The bends were also meant to produce some labial bodily movement.

Moreover, the correction of the anteroposterior problem with the use of Class III elastics was likely to cause clockwise rotation of the mandible by incorporating an extrusive component in the molars.<sup>27</sup> One strategy to limit this side effect is the simultaneous use of a chin-cup—preferably vertical<sup>14</sup> or combined with vertical elastics.<sup>27</sup>

In comparing the pretreatment and posttreatment records, the changes observed in the SNA (increase of 3°) and ANB (increase of 3°) angles, with the SNB angle unaltered (80°), suggest maxillary advancement and maintenance of the mandibular position. On the other hand, it would be more reasonable to admit that in this case a dentoalveolar sagittal correction was achieved using intermaxillary Class III elastic mechanics, which caused the maxillary teeth to protrude and the mandibular teeth to

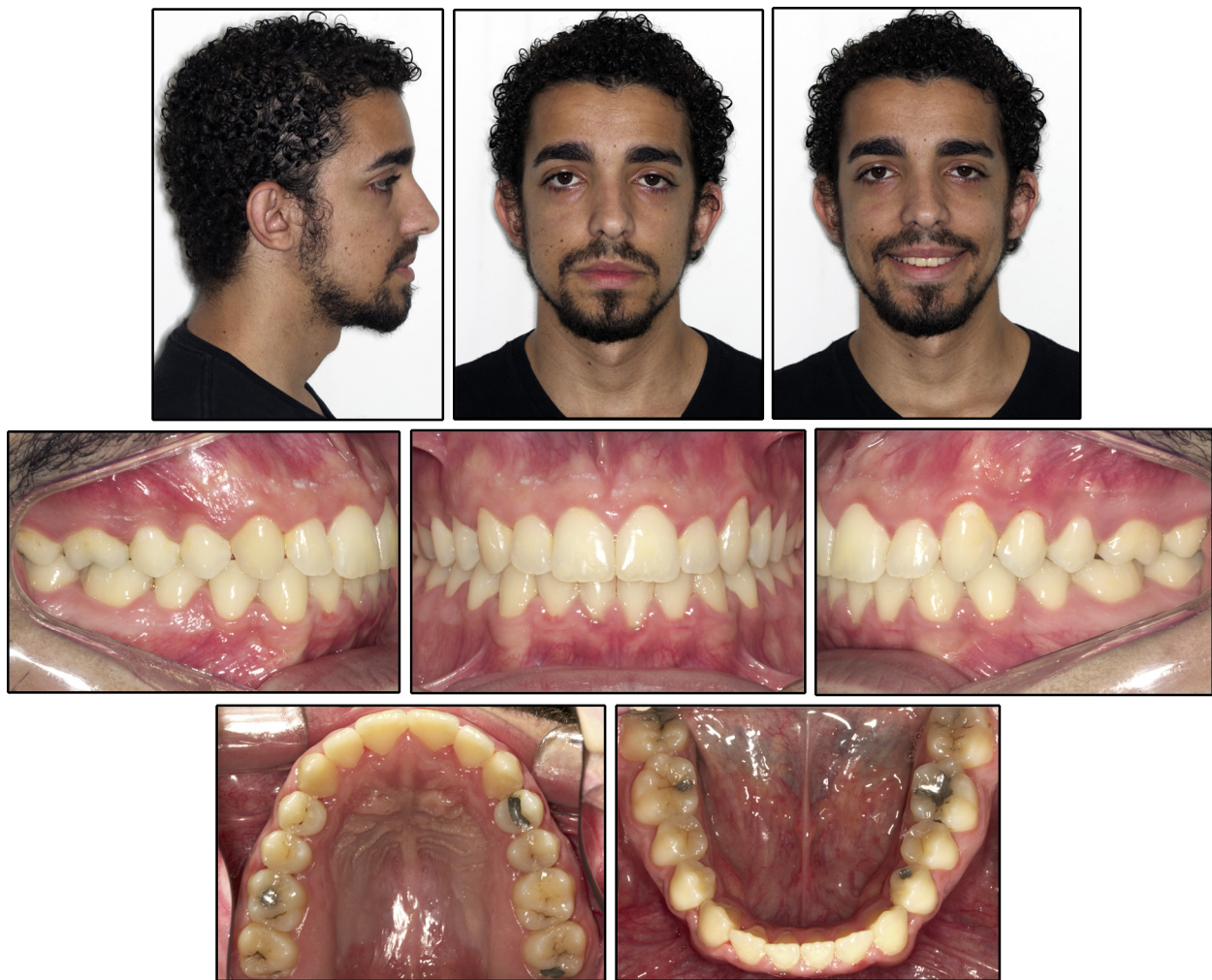retract, because of the changes in the values of 1-NA, 1.NA, 1-NB, and 1.NB mentioned above.

One major concern regarded the end of the growth period and the fear that the patient's condition might relapse. Elastic use was periodically discontinued and resumed until we felt reassured that little or no growth remained. This explains the long time of active treatment (67 months).

The decision not to use any retainer was based on the premise that correction of anterior or posterior crossbites does not require retention, because the occlusion itself plays the role of a retainer if proper tooth contacts are established.<sup>18,28</sup> Although this patient did not exhibit any significant signs of prognathism, when some residual mandibular growth does occur, often after age 18, the absence of a retainer would allow a spontaneous lingual offset of the mandibular incisors and a buccal offset of the maxillary incisors, without compromising the relationship between them. A proper overjet and overbite, in addition to the absence of clockwise mandibular rotation after treatment, certainly contributed to the patient's stability 5 years after removal of the fixed appliance without the use of a retainer.

## CONCLUSIONS

The favorable results achieved in this case report show that it is possible to correct transverse and sagittal maxillary deficiencies during the active growth phase by means of RME followed by Class III and anterior vertical elastics supported on hooks placed on the fixed



**Fig 14.** Facial and intraoral photographs at the 4-year follow-up.

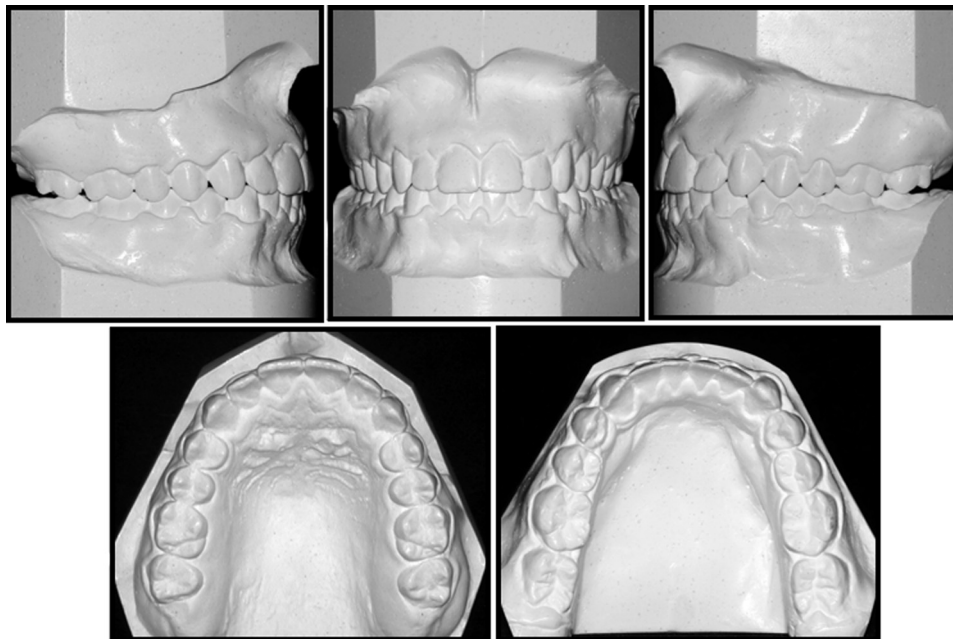
appliance. The stability that was observed 4 years after the end of treatment without retention suggests that evaluating whether some remaining growth should be expected, and ensuring appropriate relationships and occlusal contacts, proper overjet and overbite, and optimal function without increasing the mandibular plane angle during treatment, all combine in maintaining the long-term results.

#### ACKNOWLEDGMENTS

We thank the following residents of the orthodontics program of Fluminense Federal University who contributed to the treatment reported in this article: Ana Luiza Luz Fernandes da Silva, Eduardo Kant Colunga Rothier, Larissa Bustamante Capucho Brandão, and Luciana Hosken Souto.

#### REFERENCES

1. Massler M, Frankel JM. Prevalence of malocclusion in children aged 14 to 18 years. *Am J Orthod* 1951;37:751-68.
2. Grando G, Young AA, Vedovello Filho M, Vedovello SA, Ramirez-Yañez GO. Prevalence of malocclusions in a young Brazilian population. *Int J Orthod Milwaukee* 2008;19:13-6.
3. Deguchi T, McNamara JA Jr. Craniofacial adaptations induced chin cup therapy in Class III patients. *Am J Orthod Dentofacial Orthop* 1999;115:175-82.
4. Macdonald KE, Kapust AJ, Turley PK. Cephalometric changes after the correction of Class III malocclusion with maxillary expansion/face mask therapy. *Am J Orthod Dentofacial Orthop* 1999;116:13-24.
5. Da Silva Filho OG, Magro AC, Capelozza Filho L. Early treatment of Class III malocclusion with rapid maxillary expansion and maxillary protraction. *Am J Orthod Dentofacial Orthop* 1998;113:196-203.
6. Garattini G, Levrini L, Crozzoli P, Levrini A. Skeletal and dental modifications produced by the bionator III appliance. *Am J Orthod Dentofacial Orthop* 1998;114:40-4.



**Fig 15.** Dental casts at the 4-year follow-up.

7. Loh MK, Kerr WJ. The function regulator III: effects and indications for use. *Br J Orthod* 1985;12:153-7.
8. Mora DR, Oberti G, Ealo M, Baccetti T. Camouflage of moderate Class III malocclusions with extraction of lower second molars and mandibular cervical headgear. *Prog Orthod* 2007;8:300-7.
9. Ferro A, Nucci LP, Ferro F, Gallo C. Long-term stability of skeletal Class III patients treated with splints, Class III elastics and chin cup. *Am J Orthod Dentofacial Orthop* 2003;123:423-34.
10. He S, Gao J, Wamalwa P, Wang Y, Zou S, Chen S. Camouflage treatment of skeletal Class III malocclusion with multiloop edge-wise arch wire and modified Class III elastics by maxillary mini-implant anchorage. *Angle Orthod* 2013;83:630-40.
11. Macey-Dare LV. The early management of Class III malocclusions using protraction headgear. *Dent Update* 2000;27:508-13.
12. Battagel JM, Orton HS. Class III malocclusion: the post-retention findings following a non-extraction approach. *Eur J Orthod* 1993;15:45-55.
13. Stensland A, Wisth PJ, Boe OE. Dentofacial changes in children with negative overjet treated by a combined orthodontic and orthopaedic approach. *Eur J Orthod* 1988;10:39-51.
14. Haas AJ. Long-term posttreatment evaluation of rapid palatal expansion. *Angle Orthod* 1980;50:189-217.
15. Haas AJ. Palatal expansion; just the beginning of dentofacial orthopedics. *Am J Orthod* 1970;57:219-55.
16. Cevidanes L, Baccetti T, Franchi L, McNamara JA Jr, De Clerck H. Comparison of two protocols for maxillary protraction: bone anchors versus face mask with rapid maxillary expansion. *Angle Orthod* 2010;80:799-806.
17. Araújo EA, Araújo CV. Non-surgical approaches to Class III malocclusions treatment. *Rev Dent Press Ortodon Ortop* 2008;13:129-57.
18. Riedel RA. The review of the retention problem. *Angle Orthod* 1960;30:179-99.
19. Haas AJ. Rapid expansion of the maxillary dental arch and nasal cavity by opening the midpalatal suture. *Angle Orthod* 1961;31:73-9.
20. Kama JD, Ozer T, Baran S. Orthodontic and orthopaedic changes associated with treatment in subjects with Class III malocclusions. *Eur J Orthod* 2006;28:496-502.
21. Figueiredo MA, Siqueira DF, Bommarito S, Scanavini MA. Orthodontic compensation in skeletal Class III malocclusion: a case report. *World J Orthod* 2007;8:385-96.
22. Björk A, Skieller V. Facial development and tooth eruption. An implant study at the age of puberty. *Am J Orthod* 1972;62:339-83.
23. Chung CH, Font B. Skeletal and dental changes in the sagittal, vertical, and transverse dimensions after rapid palatal expansion. *Am J Orthod Dentofacial Orthop* 2004;126:569-75.
24. Ramoglu SI, Sari Z. Maxillary expansion in the mixed dentition: rapid or semi-rapid? *Eur J Orthod* 2010;32:11-8.
25. Chang JY, McNamara JA Jr, Herberger TA. A longitudinal study of skeletal side effects induced by rapid maxillary expansion. *Am J Orthod Dentofacial Orthop* 1997;112:330-7.
26. Reed N, Ghosh J, Nanda RS. Comparison of treatment outcomes with banded and bonded rapid palatal expansion appliances. *Am J Orthod Dentofacial Orthop* 1999;116:31-40.
27. Tweed CH. *Clinical orthodontics, Volume 2*. St Louis: C. V. Mosby; 1966. p. 946.
28. Kaplan H. The logic of modern retention procedures. *Am J Orthod Dentofacial Orthop* 1988;93:325-40.